

PC3

## Why You Should Be Thinking About Positional Cervical Cord Compression

by Andrew J. Holman, M.D.  
Pacific Rheumatology Associates

To be honest, I didn't even know what I was doing in Portland, Oregon, ten years ago, invited by the National Fibromyalgia Research Association (NFRA)\* along with about 25 other clinicians to discuss new ideas to better manage and understand fibromyalgia (FM). Each of us, as architects of our own glass house, had been asked to participate in what was essentially a 'think tank'. We were locked together (metaphorically speaking) in the Benson Hotel in Portland. The NFRA hoped something productive might emerge from this cauldron of peculiar ideas and discordant perspectives.

Working on an essential component of FM pathogenesis, I was in the midst of developing a construct whereby autonomic fragmentation of normal sleep (from sympathetic hyperactivity) was related to the CNS neurotransmitter, dopamine.<sup>1,2</sup> Its central messenger role beyond pain modulation, essential for initiating the chemical signal that dampens or inhibits fight-or-flight activity, was just emerging. While the pharmaceutical world focused on GABA, serotonin, and norepinephrine as essential FM/pain neurotransmitters (and still does), dopamine was about to become a major player.

Other speakers had similarly off-beat ideas, yet all listened with an open mind, patiently assimilating each intriguing proposal from a diverse array of physicians, scientists, naturopaths, chiropractors, physical therapists, and nutritionists. The ensemble met behind closed doors, without the press, without patients, and without any other stakeholders.

At first, I didn't expect much from the motley crew. And so, there I was waiting my turn, batting third, behind a neurosurgeon who admitted having little interest in FM, per se, and a scientist whose current patients were the small, furry variety, long-tailed and mute. Indeed, I admit I was skeptical, but I also admit that I couldn't have been more

wrong. At that assembly of disparate philosophies, there was a singular magic; also, two major developments emerged: one you know of and one you likely don't. The first was milnacipran (Savella®, Cypress Bioscience and Forrest Labs), the drug eventually to become the third FDA-approved medication for fibromyalgia. The second was positional cervical cord compression or PC3.

Dan Heffez, M.D., a serious and even taciturn, Johns Hopkins-trained neurosurgeon from Chicago, quite intentionally professed little interest in FM. I found this not surprising, as I had never met a neurosurgeon interested in FM. And certainly, the clinical ambiguity that mingles within FM could understandably confound surgeons unable to undo their interventions. Yet Heffez, undaunted, made two important observations, and I suspect it was his distance from classical FM thinking that allowed him to do so.

He stated that contemporary descriptions of FM overlapped considerably with historical characterization of cervical myelopathy (the general term for spinal cord pathology in the neck). He also observed that surgical repair begat improvement in FM and occasionally its resolution in that subset of myelopathy patients who had concurrent FM.<sup>3,4</sup> Typically, cervical cord compression stemmed from degenerative or traumatic disc disease. However, his observations were also borne out for those patients with FM and the Chiari I malformation (a congenital disorder that causes compression of the cerebellum, brainstem and upper cervical cord).

Chiari/FM reports had already initiated an alarmist uproar from many clinicians interested in FM. To wit, I had noted years before that many of my colleagues were prepared, if not eager, to throw that baby out with the bathwater. In an effort to protect vulnerable FM patients from surgery, few

---

© Copyright 2012, Andrew Holman, M.D. All rights reserved. This article may not be reprinted in any medium without the prior permission of Dr. Holman and notification of the National Fibromyalgia Partnership.

\* The National Fibromyalgia Research Association of Salem, Oregon, is a non-profit organization founded in 1992 by Jack Scott. Since its inception, the NFRA has funded research and professional education projects. The programs described above were organized by Rae Marie Gleason, Executive Director of the NFRA at that time, and were funded by Mr. Scott on behalf of the NFRA.

if any clinicians wanted to hear anything more about the Chiari malformation, myelopathy, or anything else related to these concepts, and, they predictably ridiculed anyone who tried.

Yet at this forum, Heffez was neither interrupted nor scolded by irate physicians. At long last, he was finally afforded ample opportunity to explain his position. He elaborated that Chiari I was simply a readily identifiable condition leading to cervical cord and lower brainstem compression. Its consequences were recognizable, well studied, and overlapped considerably with FM symptomatology. Following this introduction to craniocervical anatomy, he moved on to something even much more common.

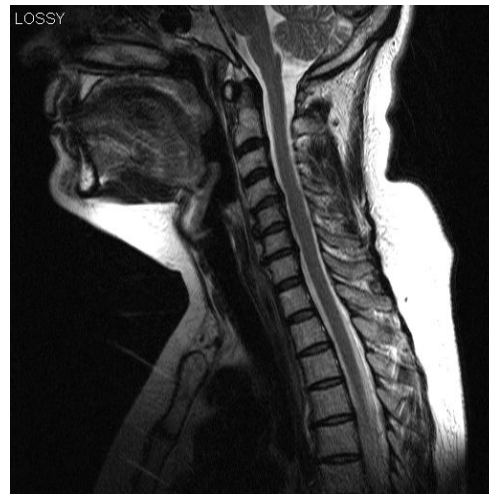Heffez proposed a new and analogous possibility – one, that to my knowledge, had not been previously advanced. He presented magnetic resonance (MR) images of the cervical spine, not simply in the traditional neutral view offered by all MRI facilities, but also in midline sagittal views, with the neck bent forward in flexion and with the neck bent back in extension. While not difficult to accomplish, no one had pursued this for reasons not difficult to understand. The MRI is a multi-million dollar instrument. Repositioning patients takes time and effort not reimbursed by insurance carriers. Besides, relative to classic radiographs and even computed tomography (CT), MR images already provided exceptional detail and clinical information. So, why the additional views and bother?

Well, no one knows what's under a rock – until it's turned.

Heffez showed an example of a classic neutral MRI view demonstrating modest disc bulges, arguably inconsequential in anyone's assessment. In flexion, the spinal canal was similarly patent with even some retraction of disc material from the spinal canal. But, in extension, with the head back, the spinal cord was pinched from a disc unexpectedly more prominent. Also completely unsuspected, the ligamentum flavum, which makes up a portion of the back wall of the cervical spinal canal, buckled like a knuckle pressed into the spinal cord from behind. Generally, only distortion of the neck in extension allows visualization of this injured ligament buckling. So, combined, these two unanticipated masses acted in coordinated fashion to obliterate the cerebrospinal fluid space around the cord at that level, and consequently, pinch the cord.

Heffez offered this positional cervical cord compression (PC3) as an anatomical analogy to cervical myelopathy – consistent with his examination

## FIGURES 1 & 2

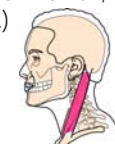
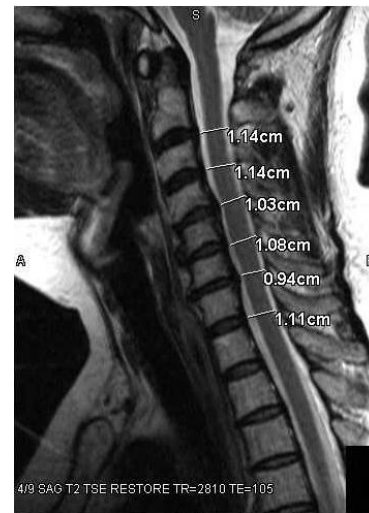

### NEUTRAL POSTURE:

Above: Classic neutral supine MRI of the neck.

At right: Same image, with spinal canal diameters at each disc level added by the radiologist.

(Images courtesy of Andrew Holman, M.D.)



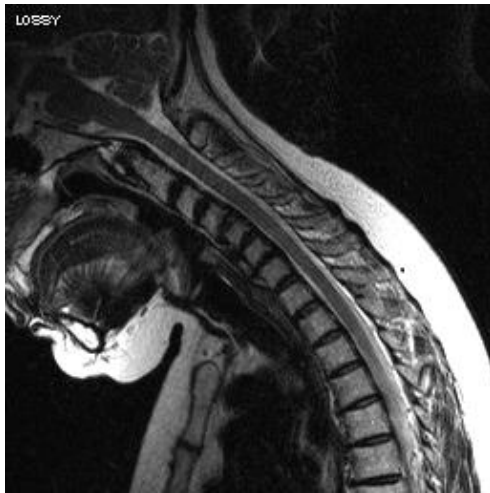4/9 SAG T2 TSE RESTORE TR=2810 TE=105  
3 graphics of head posture © photography 33 / www.fotosearch.com

findings – and as a serious cause of widespread referred pain. This evident cord compression had been missed by the best imaging technology modern medicine had to offer: the classic MRI. More than a few jaws in the audience simultaneously dropped.

Next at bat came Andrei Krassioukov, M.D., to speak about rats and spinal cord injury.<sup>5</sup> His research addressed quadriplegia, and following Heffez's revelation, I truly felt like Alice down the rabbit hole. My education was becoming stranger by the minute. I had many patients with FM, but rarely did they offer a history of significant trauma. None of them was quadriplegic. So, could such seemingly unrelated information be of any relevance to my practice? It didn't take long to learn how.

Krassioukov made a seminal comment: Abutment or light, innocuous pressure on the cervical cord in an anesthetized rat altered blood pressure and pulse rate.

**FIGURE 3**



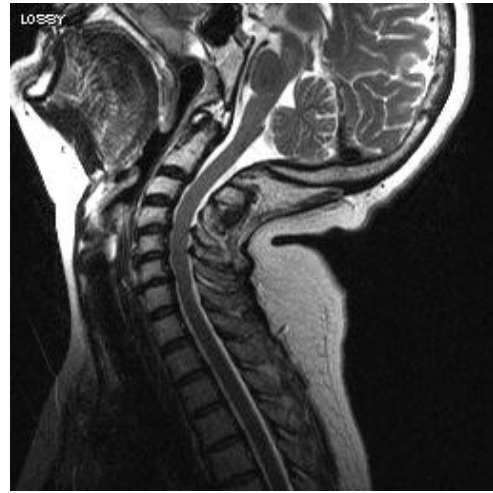**FLEXION:** Head and neck are bent forward.  
**Above:** MRI of the cervical spine. (Image courtesy of Andrew Holman, M.D.)

This was germane to Heffez’s model describing intermittent compression as an abutment to the cord in humans – not a cord injury, but an irritation. Krassioukov explained how similar thoracic or lumbar cord abutment did not have physiologic cardiovascular consequences, i.e., autonomic consequences. Interesting also was that cervical disc disease and pain is more commonly found among patients with FM than either thoracic or lumbar disease.

Heffez planted the seed, and Krassioukov applied the fertilizer. I was next – postulating how an overactive autonomic nervous system (ANS), influenced by cerebral dopamine depletion, could fragment deep sleep (stage III/IV and now termed N3) – consistent with studies that appeared to cause features of FM experimentally.<sup>6-8</sup> The impact and connection of their lectures to my conception of FM patient care had sprouted.

I had hoped to reduce FM pain, fatigue, dyscognition, etc., by attenuating an already overactive autonomic nervous system. I wanted to restore normal sleep by reducing autonomic arousal – to let rather than make patients sleep. Manuel Martínez-Lavín, M.D., had already documented overactive autonomic function in patients with FM.<sup>9,10</sup> Could positional cervical cord compression (PC3) as an unanticipated and hidden cause of autonomic activation sabotage my treatment paradigm? It certainly seemed possible. Other known autonomic arousal could do so, including pain, stress, fear, a crying child, abuse,

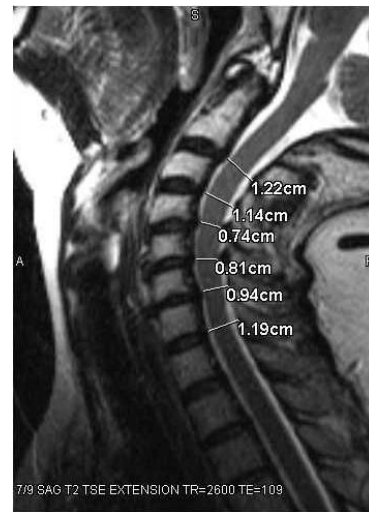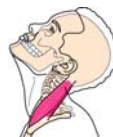**FIGURES 4 & 5**



**EXTENSION:**  
 Head and neck are bent backward.  
**Above:** Extension MRI of the cervical spine.

**At Right:**  
 Measurements of cervical spinal canal again shown.

(Images courtesy of Andrew Holman, M.D.)



etc. Each arousal could act to block restoration of normal, restorative, deep sleep.

It was also known that some patients reported onset of FM after cervical spine injuries, often as a presumed consequence to motor vehicle accidents.<sup>11</sup> Yet strangely, that hadn’t been a prominent topic of discussion in my practice. Notwithstanding, I figured that there could indeed be a patient or two who might benefit from this modified flexion-extension MRI concept. At least a couple....

Today, I laugh out loud when I recall how naïve I was sitting, listening, and considering the consequences of what I had just heard, locked up in that small conference room in the Benson Hotel in 2002.

**THE FIRST HURDLE**

The concept of PC3 might have withered right then and there if not for the generosity of Ken Reger

M.D., a MRI radiologist at Valley Radiologists in Renton, WA. You would think that this kind of scientific exploration would be the exclusive province of the National Institutes of Health (NIH) or some laudable university, but not this time. Ken offered something not unique in medicine, but rarely publicized: an unheralded generosity and cooperative spirit that elevated patient need as his sole priority.

I spoke with him about Heffez's suggestion and how he had modified the cervical MRI by including two additional sagittal views in flexion and extension. Could we do it, too? Could we get the proper equipment, software, and technical support? He said we could – but there was a problem.

I distinctly remember looking back at him waiting for the other shoe to drop. Sure, our institution had the same MRI that Heffez used, but there was a problem. In fact, any MRI facility worldwide could do it, but still, there was a problem. We wouldn't get paid.

Yes, the radiologists would be compensated for the classic cervical MRI, but not for the extra fifteen minutes required to reposition and scan the patients. I suspect that we both had the same thought. How about we do it anyway ... maybe for a single patient. The first subject for any new diagnostic tool generally has the most obvious need. So, of course, it was positive, and as the cliché goes: the rest is history. At last count, the Valley Medical Center experience for the flexion-extension, cervical spine MRI exceeded 3,000 patients.

As clinicians, we may have many reasons to suspect a problem like myelopathy – neurological deficits, muscular spasm, abnormal reflexes, poor balance, neck pain with extension. We know that some problem exists, and the trick is obtaining proof. The new MRI protocol was simply confirmatory. Many local hospitals decline to offer this study, especially our more prestigious, well-respected institutions, but this is expected to change. Currently, there are eight locations that follow the protocol devised by Heffez: five in Seattle, two in Portland, Oregon, and one in Milwaukee, Wisconsin, where Dan Heffez practices.

## SCIENCE

In 1998, the famous radiology professor, Donald Resnick, M.D., documented variable narrowing of cervical neuroforamina with neck positioning,<sup>12</sup> but

the spinal cord was not similarly investigated at the time. However, subsequent consideration of dynamic change to the spinal canal with neck movement was probably inevitable. Dan Heffez reviewed his data of surgical outcomes, but clinical characteristics of PC3 in a non-surgical population were not presented until 2006 at another NFRA meeting and later published in 2008 in *The Journal of Pain*.<sup>13</sup> For that monthly edition, *J Pain* editors decided to put the three images on their cover (neutral, flexion, and extension positions of the neck and cervical spine). Although it's not *Rolling Stone* magazine, it might just be the best a rheumatologist could hope for.

During two months chosen at random, 71% of all patients presenting with fibromyalgia at Pacific Rheumatology Associates were found to also have unsuspected PC3. The most common discs involved were those most commonly affected by post-traumatic and degenerative disc disease. Of note, only 21% of patients with PC3 would have received confirmation of cord compression had they received only the standard neutral views. Thus, 4 of 5 patients with PC3 are missed if one relies solely on a traditional cervical spine MRI.

The *J Pain* paper also assessed patients referred for FM, yet without sufficient tender point count to confirm FM. This has been a contentious issue for many clinicians, particularly our European colleagues. In fact, this concern – of what really constitutes FM (widespread pain or tenderness to light touch [allodynia]) – has prompted recent adoption of a revised diagnostic approach to FM.<sup>14</sup> By 1990 American College of Rheumatology criteria, FM is classified by at least three months of widespread pain and at least 11 of 18 specific tender points.<sup>15</sup> The new approach tabulates areas of pain by questionnaire and does not require a physical examination for tenderness.

For many years, clinicians have struggled with the veracity of FM because so many of their patients with the fatigue, muscular spasm, widespread pain, sleep disturbance and dyscognition of FM lack sufficient tender points, i.e., widespread allodynia. In the *J Pain* paper, 85% of these patients had PC3. This observation raises the question of whether or not PC3 alone presents as widespread pain without allodynia. Most likely, PC3 is an entity unto itself, but it can also be an important cause of pain, autonomic arousal, and hence, secondary FM.

Of note, there were two classic Chiari malformations identified among the *J Pain* study partici-

pants in addition to one case each of unsuspected multiple myeloma (MM) and multiple sclerosis (MS). It should be noted, however, that these were the only two cases found among the current data base of flexion-extension C-spine MRIs to date. Although FM can coexist with any disorder (with the probable exception of the high dopamine state, schizophrenia), there is no reason to infer that MS and MM are likely to be better identified with this modified MRI protocol.

Heffez has since explained that PC3 manifests the aging of an injury, one often occurring ten to thirty years previously.<sup>16</sup> Many patients with PC3 do not recall a specific injury, but clearly the MRI demonstrates disruption of the ligamentum flavum and the corresponding disc. What the enhanced MRI clarifies is the actual severity of the anatomical disruption and impingement of the cord with varied position. And, narrowing of a cervical spinal canal (normal 13-15 mm) to 8-10mm or as low as 4-6 mm, while both painful, has very different treatment implications.

Curiously, the cord is not considered injured and there is usually no tissue damage. Rather, PC3 is thought to reflect spinal cord irritation. There are no 'cord signals' by MRI to alert the radiologist. There is usually no evidence of spinal cord atrophy, scarring, or thinning (myelomalacia). There may be flattening of the cord, and this is not uncommonly reported on traditional C-spine MRI reports. But generally, without the extension views, it has remained enigmatic exactly why a cord would be flattened. Perhaps for some, this mystery may now have a suitable explanation in PC3.

Clinically, patients with PC3 generally abhor cervical extension, such as being positioned in a hair dresser's sink for any significant length of time, or in a dentist's chair, looking at the stars or firework displays, reading a computer screen over reading glasses, or riding a bicycle (non-recumbent). They may notice a variety of neurologic symptoms quite separate from the pain, such as fatigue and sleep disturbance that characterize FM. Asymmetric grip strength, poor balance (especially with eyes closed), numbness, tingling throughout the body, dizziness, and gait disturbances are common.

In fact, the first and only controlled study using a detailed neurological examination in patients with FM compared to age-matched controls reported in 2009 that 70% of patients with FM had objective neurological deficits<sup>1</sup> – not simply neurological complaints, but impairment. The

authors concluded that PC3 might be a reasonable explanation.

Autonomically-mediated processes are also commonly identified in patients with FM. These include temperature dysregulation, abnormal sweating, gastrointestinal issues such as irritable bowel syndrome and gastric hyperacidity, bladder irregularities, and cardiovascular concerns such as palpitation and atypical (non-cardiac) chest pain. Again, as a potent autonomic arousal in animal models, comorbid PC3 might suggest a plausible rationale.

Finally, the Seattle experience has been confirmed, at least in one study. In Portland, Cheryl Hryciw, ARNP, reported that 55% of a cohort of her patients with FM evaluated at the Oregon Health & Science University also had PC3.<sup>18</sup> In addition, she found that 50% of those with PC3 had obstructive sleep apnea – another well-studied and documented autonomic arousal. And finally, a 2011 paper in *Neurosurgery* went so far as to recommend that patients with FM undergo only a flexion-extension rather than traditional cervical MRI when evaluating the neck.<sup>19</sup>

## TREATMENT

### *Physical Therapy*

In 2002, the only reported treatment of PC3 was surgical, but in the intervening ten years, only 15% of patients in Seattle with even significant spinal cord compression have required surgical decompression. The other 85% have often benefited from a new, innovative physical therapy program developed locally to address PC3. Admittedly, I was skeptical about physical therapy, because I had offered it unsuccessfully for many years to patients suffering from FM and cervical pain. Often, it merely exacerbated their pain. However, the PC3 program is significantly different and best envisioned as spinal cord centric, not a reemphasis on arthritic or degenerative disc disease.

Two fundamental concerns are addressed in the PC3 program. First, patients with FM have poor position sense, i.e., awareness of their postural alignment. This has also been observed



© LifeArt / www.fotosearch.com

in patients with benign joint hypermobility (BJH). Not surprisingly, BJH is common among patients with FM<sup>20</sup> and within their families. Some suggest that this is because BJH, in addition to ligamentous laxity, is also associated with a tendency to develop partial autonomic instability.<sup>21</sup> In addition, autonomic arousal, if sufficiently active, can chronically fragment deep, restorative sleep – arguably an integral component of FM pathophysiology.

The second phase of PC3 therapy acts to support and stabilize an injured and redundant ligamentum flavum that bulges into the spinal cord with extension. The exact reason for success continues to be a topic of ongoing research, but outcomes are encouraging. The program is available in Portland (OR) and south Seattle, but can be shared with any interested therapists and patients. Most patients with compression of the cord due to narrowing of the cervical spinal canal to 8-10 mm generally respond, while narrowing below 7mm is less predictable.

### *Surgery*

Patients with cervical canals narrowed to 4-6 mm at any disc level usually require surgical repair. The Seattle data base of one neurosurgeon particularly interested in PC3 now exceeds 420 patients. The most successful approach has been anterior disc fusion with internal fixation, an observation also confirmed in Portland. A hard Philadelphia collar is required for a month post-operatively followed by the same PC3 PT program for 1-2 months. Surgical patients have led the way to reveal what is actually attributable to PC3 clinically. They often note resolution or improvement not only of co-morbid FM, consistent with Heffez's first reports, but also migraines and many dysautonomic symptoms detailed above.

### *Medications*

PC3 is not a diagnosis yet validated by the FDA, but some medications may be logically applicable based on individual consultation with one's clinician. While not studied formally in PC3, the three medications already FDA-approved for fibromyalgia (pregabalin, duloxetine, milnacipran) are all postulated to work, to some degree, at the level of the spinal cord. In fact, pregabalin is approved by the EMEA<sup>22,23</sup> (the FDA equivalent in Europe) for the treatment of spinal cord injury pain – a diagnostic designation not used in the US. Consequently, some may wonder whether or not pregabalin effectively treats FM, as

documented in numerous clinical trials, or simply reduces pain, etc., by addressing co-morbid PC3.<sup>24</sup> No one knows, because FM study patients have not been screened for PC3. Only one FM randomized clinical trial to date excluded PC3 (pramipexole).<sup>25</sup>

Other off-label considerations for PC3 may include medications known to reduce neuronal excitability, such as anticonvulsants (akin to pregabalin). Analgesics, while not generally recommended for FM, could have a logical role for PC3 myelopathy. Non-steroidal anti-inflammatory drugs (NSAIDs) trials in FM have uniformly failed suggesting that PC3 might also not respond. Corticosteroids have been used for cervical myelopathy, but their adverse event profile makes them unattractive long term. Muscle relaxants may reduce secondary spasm, and some tricyclic antidepressants might address the cord. Finally, two benzodiazepines are known to reduce autonomic arousal and ameliorate restless legs syndrome (common in FM) and may be useful in patients with cervical spinal cord injury: lorazepam and clonazepam. Both are used only at bedtime (mean dose 1.8 mg) and have shown benefit and long-term safety among patients with FM,<sup>26,27</sup> but require proper monitoring and sound clinical judgment.

## FUTURE

Despite all of the above, there remains abundant PC3 research yet to be completed. Further validation of its prevalence at centers beyond the Pacific Northwest is critical along with additional corroboration of treatment outcomes. Its application in whiplash and motor vehicle accident research remains to be explored. The role of PC3 either as a trigger or mimic of migraine has fundamental importance as does consideration of positional compression higher in the cervical canal, nearer the brainstem either with the classic Chiari I malformation or the controversial Chiari 0 concept. New, more effective treatments and less expensive diagnostic tools should be explored as well as eventually completing a trial that compares asymptomatic controls to patients with PC3 (ongoing).

Yet notwithstanding, there is one concept upon which many clinicians and patients can probably agree: dynamic structures like the neck should be evaluated dynamically, with flexion and extension, and when feasible, with rotation and lateral bending. We cannot know and should not assume the state of one's anatomy without adequate visualization.

It is important to reiterate that PC3 alone is a specific entity that causes pain and fatigue in addition to being a secondary cause of FM. Studying it alone is important, but for sufferers with FM, available evidence suggests that it can be very difficult to achieve a meaningful recovery if comorbid PC3 goes unnoticed and untreated. As a potent source of autonomic arousal, PC3 may negate the beneficial effects of certain medications. Conversely, as a potential source of central, neuropathic, referred pain, PC3 may respond to other medications available to physicians interested in FM.

The classic medical record notation of ‘WNL’ doesn’t always mean ‘Within Normal Limits’. Sometimes it means ‘We Never Looked’. With the flexion-extension C-spine MRI, we can now look - and make more informed decisions about PC3 and patient care.

**About The Author:** Andrew J. Holman, M.D., is a rheumatologist in Seattle and Associate Clinical Professor of Medicine at the University of Washington. For many years, he has had an avid interest in and published articles related to fibromyalgia, complex autoimmune disease, hypermobility, and the autonomic nervous system. Additional information may be obtained at:

[www.PacificRheumatology.com](http://www.PacificRheumatology.com)

[www.PositionalCordCompression.com](http://www.PositionalCordCompression.com)

## REFERENCES

- Holman AJ, Neiman RA, Ettlinger RE: Preliminary efficacy of the dopamine agonist, pramipexole for fibromyalgia: the first, open label, multicenter experience. *J Musculoskeletal Pain* 2004;12(1):69-74.
- Holman AJ. Pramipexole and fibromyalgia: promise and precaution. [letter] *J Rheum* 2003;30(12):2733.
- Heffez DS, Ross RE, Shade-Zeldow Y, Kostas K, Shah S, Gottschalk R, Elias DA, Shepard A, Leurgans SE, Moore CG. Clinical evidence for cervical myelopathy due to Chiari malformation and spinal stenosis in a non-randomized group of patients with the diagnosis of fibromyalgia. *Eur Spine J*. 2004;13(6):516-23.
- Heffez DS, Ross RE, Shade-Zeldow Y, Kostas K, Morrissey M, Elias DA, Shepard A. Treatment of cervical myelopathy in patients with the fibromyalgia syndrome: outcomes and implications. *Eur Spine J* 2007;16(9):1423-33.
- Krassioukov AV, Fehlings MG. Effect of graded spinal cord compression on cardiovascular neurons in the rostro-ventro-lateral medulla. *Neuroscience* 1999;88(3):959-973.
- Moldofsky H, Scarisbrick P. Induction of neurasthenic musculoskeletal pain syndrome by selective sleep stage deprivation. *Psychosom Med*. 1976;38(1):35-44.
- Moldofsky H, Scarisbrick P, England R, Smythe H. Musculoskeletal symptoms and non-REM sleep disturbance in patients with ‘fibrositis syndrome’ and healthy subjects. *Psychosom Med* 1975;37:341-351.
- Lentz MJ, Landis CA, Rothermel J, Shaver JL. Effects of selective slow wave sleep disruption on musculoskeletal pain and fatigue in middle aged women. *J Rheumatol*. 1999;26(7):1586-92.
- Martinez-Lavin M, Hermsillo AG: Autonomic nervous system dysfunction may explain the multisystem features of fibromyalgia. *Semin Arthritis Rheum* 2000;29(4):197-199.
- Martinez-Lavin M, Hermsillo AG, Rosas M, Soto M: Circadian studies of autonomic nervous balance in patients with fibromyalgia: a heart variability analysis. *Arthritis Rheum*. 1998;41(11):1966-1971.
- Buskila D, Neumann L, Vaisberg G, Alkalay D, Wolfe F. Increased rates of fibromyalgia following cervical spine injury. A controlled study of 161 cases of traumatic injury. *Arthritis Rheum*. 1997;40(3):446-52.
- Muhle C, Resnick D, Ahn JM, Sudmeyer M, Heller M. In vivo changes in the neuroforaminal size at flexion-extension and axial rotation of the cervical spine in healthy persons examined using kinematic magnetic resonance imaging. *Spine* 2001;26(13):E287-93.
- Holman AJ. Positional cervical spinal cord compression and fibromyalgia: a novel comorbidity with important diagnostic and treatment implications. *J Pain* 2008;9(7):613-22.
- Wolfe F, Clauw DJ, Fitzcharles MA, Goldenberg DL, Katz RS, Mease P, Russell AS, Russell IJ, Winfield JB, Yunus MB. The American College of Rheumatology diagnostic criteria for fibromyalgia and measurement of symptom severity. *Arthritis Care Res (Hoboken)*. 2010;62(5):600-10.
- Wolfe F, Smythe HA, Yunus MB, Bennett RM, Bombadier C, Goldenberg DL, Tugwell P, Campbell SM, Abeles M, Clark P, Fam AG, Farber SJ, Fiechtner JJ, Franklin CM, Gatter RA, Hamaty D, Lessard J, Lichtbroun AS, Masi AT, McCain GA, Reynolds WJ, Romano TJ, Russell IJ, Sheon RP. The American College of Rheumatology 1990 criteria for the classification of fibromyalgia: report of the multicenter criteria committee. *Arthritis Rheum* 1990;33(2):160-172.
- Personal communication.
- Watson NF, Buchwald D, Goldberg J, Noonan C, Ellenbogen RG. Neurologic signs and symptoms in fibromyalgia. *Arthritis Rheum* 2009;60(9):2839-2844.
- Hryciw CA, Holman AJ. Positional cervical cord compression (PC3) as a comorbidity in patients with fibromyalgia (FM): findings from a one-year retrospective study at an FM referral university [abstract]. Presented at MYOPAIN 2010, Toledo, Spain.
- Watson NF, Buchwald D, Goldberg J, Maravilla KR, Noonan C, Guan Q, Ellenbogen RG. Is Chiari I malformation associated with fibromyalgia? *Neurosurgery* 2011;68:443-449.
- Hudson N, Fitzcharles MA, Cohen M, Starr MR, Esdaile JM. The association of soft-tissue rheumatism and hypermobility. *Br J Rheumatol*. 1998;37(4):382-6.
- Gazit Y, Nahir AM, Grahame R, Jacob G. Dysautonomia in the joint hypermobility syndrome. *Am J Med*. 2003 Jul;115(1):33-40.
- Siddall PJ, Cousins MJ, Otte A, Griesing T, Chambers R, Murphy TK. Pregabalin in central neuropathic pain associated with spinal cord injury: a placebo controlled trial. *Neurology* 2006 28;67(10):1792-800.
- [http://www.emea.europa.eu/ema/index.jsp?curl=pages/medicines/human/medicines/000546/human\\_med\\_000894.jsp&mid=WC0b01ac058001d124/](http://www.emea.europa.eu/ema/index.jsp?curl=pages/medicines/human/medicines/000546/human_med_000894.jsp&mid=WC0b01ac058001d124/)
- Holman AJ. Pregabalin for treatment of fibromyalgia: the rest of the story? [review] *Current Pain and Headache Reports*. 2009;13(6):420-22.
- Holman AJ, Myers RR. A randomized, double-blind, placebo controlled trial of pramipexole, a dopamine agonist, in patients with fibromyalgia receiving concomitant medications. *Arthritis Rheum* 2005;52(8):2495-2505.
- Holman AJ: Effect of Lorazepam on Pain Score for Refractory Fibromyalgia [abstract]. *Arthritis Rheum* 1998;41(9):S259.
- Holman AJ: Safety and Efficacy of Lorazepam for Fibromyalgia after One Year. [abstract] *Arthritis Rheum* 1999;42(9):S152.